JOGECA Journal of Obstetrics and Gynaecology of Eastern and Central Africa

CASE REPORT

Adolescent Gynecology

Chronic pelvic pain secondary to a unicornuate uterus with a noncommunicating rudimentary horn in an adolescent: a case report

Mokeira Osando[1]*, Saadia H. Mohammed[1], Philomena Owende[2], James Amenge[2]

1. Department of Obstetrics and Gynecology, University of Nairobi, Nairobi, Kenya
2. Department of Obstetrics and Gynecology, Kenyatta National Hospital, Nairobi, Kenya

***Correspondence:** drmokeiralo@gmail.com

Received: 13 March 2025; Revised: 4 June 2026; Accepted: 9 June 2026; Available online: June 2026
DOI: 10.59692/x5emm046

Copyright © 2026, The authors. Published by JOGECA. This is an open access article under the terms of the Creative Commons Attribution 4.0 International License (http://creativecommons.org/licenses/by/4.0/), which permits unrestricted reuse, distribution, and reproduction in any medium provided the original author(s) and the source are properly cited.

Abstract

Background: A unicornuate uterus is a rare Müllerian anomaly resulting from complete or partial failure of development of one Müllerian duct. Affected adolescents may present with dysmenorrhea or chronic pelvic pain when a functional noncommunicating rudimentary horn is present. We report a case of chronic pelvic pain associated with noncommunicating rudimentary horn and ipsilateral hematosalpinx in an adolescent.

Case presentation: A 15-year-old presented with a 2-year history of intermittent lower abdominal pain that worsened during menstruation. Pelvic ultrasonography demonstrated a left adnexal mass initially interpreted as an endometrioma. Hysteroscopy demonstrated a single cervix, a single uterine cavity, and right tubal ostium. Laparoscopy and chromopertubation confirmed a left unicornuate uterus with a noncommunicating rudimentary horn and ipsilateral hematosalpinx. Laparoscopic excision of the rudimentary horn with ipsilateral salpingectomy were performed. At 3-month follow-up visit, the patient remained asymptomatic.

Conclusion: Müllerian anomalies should be considered in adolescents presenting with chronic pelvic pain and dysmenorrhea. When initial imaging is inconclusive or suggests an adnexal lesion, further evaluation of uterine anatomy may be necessary. Hysteroscopy and laparoscopy provided complementary diagnostic information and enabled definitive surgical management in this case.

Keywords: Chronic pelvic pain, Müllerian anomaly, Unicornuate uterus, Rudimentary horn

Introduction

A unicornuate uterus is a Müllerian anomaly resulting from complete or partial failure of development of one Müllerian duct (1,2). It may be associated with a communicating or noncommunicating rudimentary horn, a rudimentary horn without an endometrial cavity, or no rudimentary horn. Adolescents with a unicornuate uterus with a functioning noncommunicating rudimentary horn may present with dysmenorrhea and pelvic pain (3–6). When a noncommunicating rudimentary horn contains functional endometrium, menstrual blood may accumulate within the horn because of an obstructed outflow tract, resulting in hematometra and potentially, hematosalpinx, or endometriosis. Because the presenting symptoms are often mild or nonspecific in early adolescence, diagnosis is frequently delayed. This case highlights the diagnostic challenge posed by a

noncommunicating rudimentary horn that may be misidentified as an adnexal mass on initial ultrasonography in an adolescent presenting with chronic pelvic pain.

Case presentation

A 15-year-old adolescent presented with a 2-year history of intermittent lower abdominal pain that began approximately five months after menarche. The pain was intermittent, predominantly localized to the left iliac fossa, and worsened during menstruation. Her menstrual cycles were regular with normal flow. Two days before presentation to the emergency department, the pain acutely worsened and was associated with fever, chills, vomiting, and headache. There were no lower urinary tract symptoms.

On presentation, the patient appeared ill, and in pain. Her blood pressure was 121/99 mm Hg, pulse rate was 109 beats/min, and temperature was 36.7 °C. Abdominal examination, revealed rigidity, guarding, and marked tenderness in the left iliac fossa; the rectal mucosa was unremarkable. Laboratory evaluation demonstrated an elevated cancer antigen 125 (CA-125) of 227.1 U/mL and mildly elevated C-reactive protein of 7.8 mg/L. Serum β-human chorionic gonadotropin was negative. Hemoglobin concentration, white blood cell count, renal function tests, liver function tests, and coagulation profile were unremarkable.

Pelvic ultrasound revealed an anteverted, nongravid, normal size (5.3 cm x 2.9 cm x 4 cm, volume 20 cc) uterus with no myometrial lesions. A complex left mass adnexal mass measuring 4.3 x 3.4 cm was identified and interpreted as consistent with an endometrioma. A right hemorrhagic ovarian cyst measuring 3.7 cm x 3.8 cm was also noted (**Figure 1**). The initial differential diagnosis included an endometrioma and other causes of an adnexal mass associated with chronic pelvic pain. Given the patient's age, cyclic nature of the pain, and inconclusive ultrasonographic findings, further evaluation of the uterine anatomy was undertaken. Diagnostic hysteroscopy demonstrated a single uterine cavity and right tubal ostium. Laparoscopy evaluation subsequently identified a left rudimentary horn larger than the functional hemi-uterus. It was identified adjacent to the unicornuate uterus and an ipsilateral hematosalpinx. Chromopertubation demonstrated no communication between the rudimentary horn and the uterine cavity, confirming the diagnosis of a unicornuate uterus with a noncommunicating rudimentary horn (**Figure 2**).

Laparoscopic excision of the noncommunicating rudimentary horn and left salpingectomy was performed, while the functional hemi-uterus was

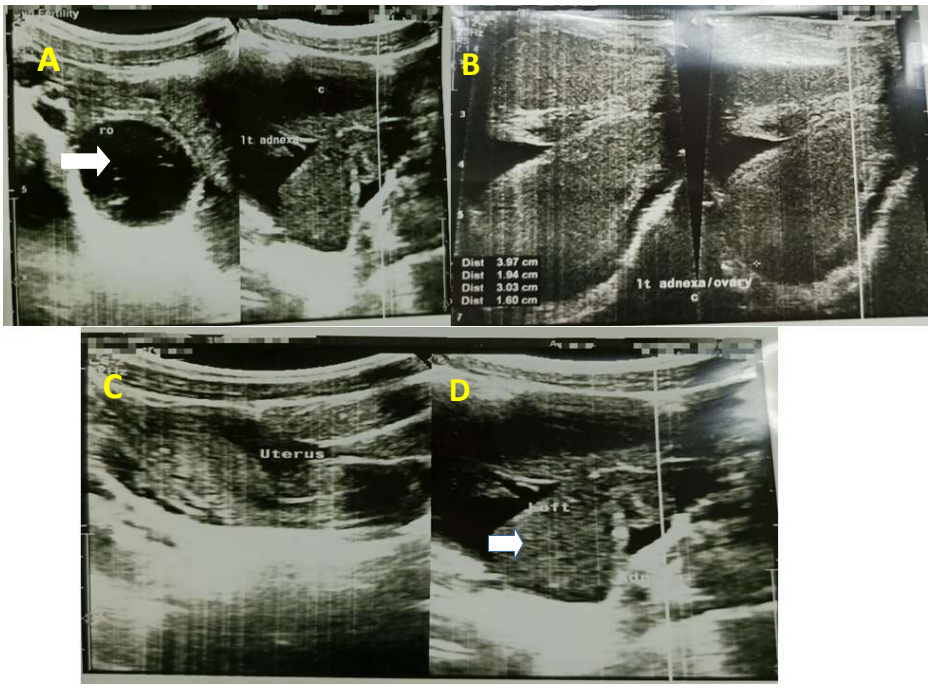

Figure 1: Pelvic ultrasonographic images. **A**: Depicts right ovary (arrow) and the left adnexa **B**: Left adnexa/ovary **C**: Uterus **D**: Left adnexal mass (arrow)

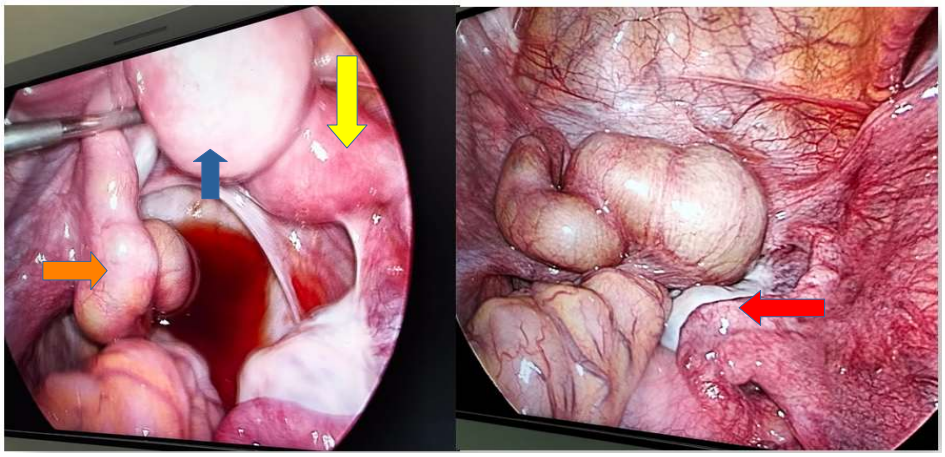

Figure 2: Laparoscopic intraoperative images showing a rudimentary horn (blue arrow) adjacent to the unicornuate uterus (yellow arrow), left hematosalpinx (orange arrow), and right ovary (red arrow).



Figure 3: Resected noncommunicating rudimentary horn specimen.

preserved (Figure 3). The resected tissues were submitted for histopathologic examination. Histopathologic examination of the resected rudimentary horn demonstrated myometrial tissue contained endometrial glands and surrounding stroma without atypia, consistent with functional endometrial tissue within the rudimentary horn (Figure 4). Examination of the fallopian tube demonstrated hemorrhage within the tubal lumen without chorionic villi (Figure 5-6). The postoperative course was uncomplicated. The patient was clinically and hemodynamically stable on postoperative day 2 and was discharged home. At the 3-month follow-up visit, she remained asymptomatic.

Discussion

The prevalence of unicornuate uterus is estimated to range between 2.4% and 13.7% of all uterine anomalies (2). However, its true incidence still remains uncertain due to challenges such as underdiagnosis, underreporting, historical variation in classification systems, and the presence of diverse anatomical variations as evidenced by case series (1,2,7). In a case series of menstruating adolescents with obstructive

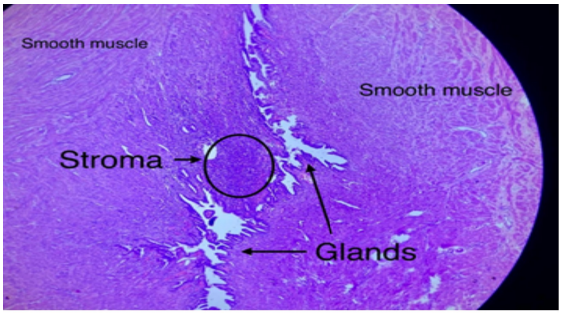

Figure 4: Histopathologic examination of the resected rudimentary horn showing myometrial tissue containing endometrial glands and surrounding stroma without atypia.

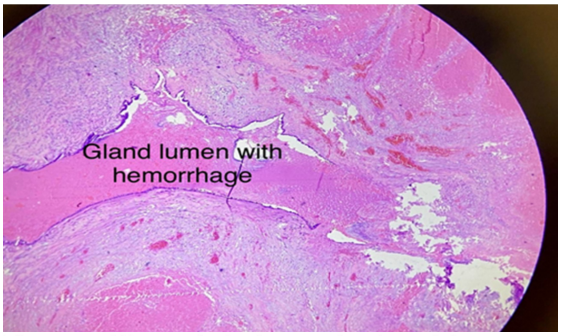

Figure 5: Histopathologic examination of the fallopian tube showing hemorrhage within the tubal lumen without chorionic villi.

Müllerian anomalies, unicornuate uterus with a noncommunicating rudimentary horn was reported as the second most frequent diagnosis (4).

Among adolescents, dysmenorrhea and pelvic pain are the most frequent presenting symptoms, often characterized by minimal or no relief with standard analgesics (4,8). Other clinical manifestations include chronic pelvic pain, endometriosis, and obstetric complications such as recurrent pregnancy loss and preterm birth. Müllerian anomalies have been associated with adverse

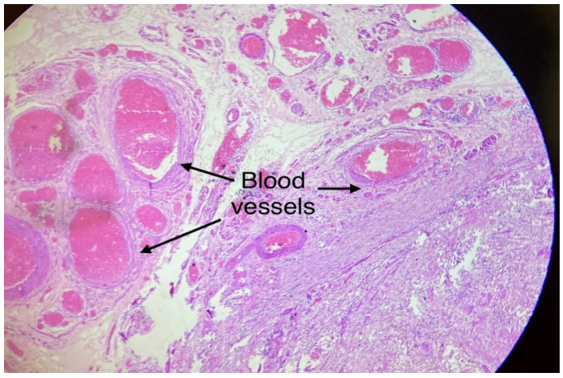

Figure 6: Histopathologic image showing dilated blood vessels.

reproductive outcomes, including miscarriage, preterm birth, fetal growth abnormalities, and uterine rupture (5,9,10). Obstructive anomalies may additionally result in hematometra, hematosalpinx, endometriosis, and chronic pelvic pain (6). The clinical presentation in this patient was consistent with an obstructive process involving the functional rudimentary horn. Her long history of cyclic pain, left iliac fossa tenderness, and bilateral adnexal tenderness suggested a unilateral obstructive process, yet the initial 2D ultrasound localized the abnormality to an adnexal mass. This case illustrates diagnostic difficulty of routine ultrasonography, as a rudimentary horn may be small, laterally positioned, or mistaken for an adnexal lesion (3).

Some studies recommend performing the ultrasound during the second half of the menstrual cycle to optimize visualization, as the endometrium is thicker at this time (8). Magnetic resonance imaging (MRI) or 3-dimensional ultrasonography can provide additional anatomical detail when a Müllerian anomaly is suspected. MRI offers multiplanar imaging capabilities that can delineate both external and internal uterine structures, facilitating differentiation among various Müllerian anomalies (11). However, some studies suggest that diagnostic laparoscopy remains valuable when imaging findings are inconclusive (12). In this case, both hysteroscopy and laparoscopy provided complementary diagnostic information. Hysteroscopy demonstrated the internal uterine cavity, whereas laparoscopy enabled direct assessment of the external uterine anatomy and facilitated definitive surgical treatment (5,13).

Given the heterogeneity of uterine anatomy and variation in classification systems, management is individualized according to symptoms, uterine anatomy, reproductive goals, and associated complications. One proposed surgical option is metroplasty, although evidence supporting its reproductive benefit remains limited (14,15). In this patient, excision of the functional noncommunicating rudimentary horn was performed to address the symptomatic obstructive anomaly and relieve pelvic pain, with the aim of reducing ongoing complications associated with retained functional endometrium.

Conclusion

This case highlights the importance of considering obstructive Müllerian anomalies in adolescents presenting with chronic cyclic pelvic pain. When ultrasonography suggests an adnexal lesion but clinical features raise suspicion of a Müllerian anomaly, further evaluation of uterine anatomy may be warranted. In this patient, hysteroscopy and laparoscopy established the diagnosis, and laparoscopic excision of the symptomatic rudimentary horn resulted in an uncomplicated postoperative course and resolution of symptoms at 3-month follow-up.

Informed consent for publication

Written Informed consent for publication of this case report and accompanying images was obtained from the patient's parent.

Declarations

Funding

No specific funding was received for this work.

Conflicts of interest

The authors have no conflicts of interest to declare.

References

1. Pfeifer SM, Attaran M, Goldstein J, et al. ASRM müllerian anomalies classification 2021. Fertil Steril. 2021;116(5):1238-1252. doi:10.1016/j.fertnstert.2021.09.025
2. Engmann L, Schmidt D, Nulsen J, Maier D, Benadiva C. An unusual anatomic variation of a unicornuate uterus with normal external uterine morphology. Fertil Steril. 2004;82(4):950-953. doi:10.1016/j.fertnstert.2004.03.043
3. Khati NJ, Frazier AA, Brindle KA. The unicornuate uterus and its variants: clinical presentation, imaging findings, and associated complications. J Ultrasound Med. 2012;31(2):319-331. doi:10.7863/jum.2012.31.2.319
4. Kapczuk K, Friebe Z, Iwaniec K, Kędzia W. Obstructive Müllerian Anomalies in Menstruating Adolescent Girls: A Report of 22 Cases. J Pediatr Adolesc Gynecol. 2018;31(3):252-257. doi:10.1016/j.jpag.2017.09.013

5. Passos IMPE, Britto RL. Diagnosis and treatment of müllerian malformations. Taiwan J Obstet Gynecol. 2020;59(2):183-188. doi:10.1016/j.tjog.2020.01.003
6. Liu MM. Unicornuate uterus with rudimentary horn. Int J Gynaecol Obstet. 1994;44(2):149-153. doi:10.1016/0020-7292(94)90070-1
7. Sánchez-Ferrer ML, Prieto-Sanchez MT, Sánchez Del Campo F. Variations in clinical presentation of unicornuate uterus with non-communicating rudimentary horn (class IIB of the American Fertility Society classification). Taiwan J Obstet Gynecol. 2018;57(1):110-114. doi:10.1016/j.tjog.2017.12.018
8. Fontana E, Parma M, Fedele F, Girardelli S, Parazzini F, Candiani M. Forty-two normomenstruating adolescents with Müllerian obstructive anomalies: Presentation, pitfalls in the dagnosis and surgical management. Acta Obstet Gynecol Scand. 2023;102(1):92-98. doi:10.1111/aogs.14454
9. Lin PC. Reproductive outcomes in women with uterine anomalies. J Womens Health (Larchmt). 2004;13(1):33-39. doi:10.1089/154099904322836438
10. Kapczuk K, Zajączkowska W, Madziar K, Kędzia W. Endometriosis in Adolescents with Obstructive Anomalies of the Reproductive Tract. J Clin Med. 2023;12(5):2007. Published 2023 Mar 3. doi:10.3390/jcm12052007
11. Marten K, Vosshenrich R, Funke M, Obenauer S, Baum F, Grabbe E. MRI in the evaluation of müllerian duct anomalies. Clin Imaging. 2003;27(5):346-350. doi:10.1016/s0899-7071(02)00587-9
12. Letterie GS, Haggerty M, Lindee G. A comparison of pelvic ultrasound and magnetic resonance imaging as diagnostic studies for müllerian tract abnormalities. Int J Fertil Menopausal Stud. 1995;40(1):34-38
13. Tlais M, Khalil LM, Haddad K, et al. The Role of Laparoscopic Surgery in Gynecological Congenital Anomalies. Maedica (Bucur). 2025;20(4):840-850. doi:10.26574/maedica.2025.20.4.840
14. Ludwin A, Lindheim SR. Unicornuate uterus and the noncommunicating functional horn: continued debate on the diagnosis, classification, and treatment. Fertil Steril. 2020;113(4):772-773. doi:10.1016/j.fertnstert.2020.01.006
15. Bhagavath B, Ludwin A, Lindheim SR. Reunification of the unicornuate uterus and the remnant horn-proceed with caution!. Fertil Steril. 2020;114(5):981-982. doi:10.1016/j.fertnstert.2020.09.136